

IF: 0.925

Asian Pacific Journal of Tropical Medicine

journal homepage: www.apjtm.org



doi: 10.4103/1995-7645.223527

©2018 by the Asian Pacific Journal of Tropical Medicine. All rights reserved.

An updated systematic review of Zika virus–linked complications

Braira Wahid^{1,2}, Amjad Ali¹✉, Muhammad Waqar^{1,2}, Muhammad Idrees^{1,2,3}

¹Centre for Applied Molecular Biology, 87–West Canal Bank Road Thokar Niaz Baig, University of the Punjab, Lahore, Pakistan

²Genome Centre for Molecular Based Diagnostics and Research Centre, Cl–25 Block B Al–Sudais Plaza Abdalian Cooperative Society, Lahore, Pakistan

³Hazara University, Mansehra, Pakistan

ARTICLE INFO

Article history:

Received 3 September 2017

Received in revised form 30 October 2017

Accepted 15 November 2017

Available online 2 January 2018

Keywords:

Zika virus

Microcephaly

Guillain–Barre syndrome

Acute myelitis

Meningoencephalitis

hydrancephaly/hydrops fetalis

Myasthenia gravis

ABSTRACT

Objective: To determine the breadth of Zika virus (ZIKV)-associated brain anomalies in neonates and adults. **Methods:** Systematic review was conducted according to Preferred Reporting Items for Systematic Reviews and Meta-Analyses (PRISMA) statement using electronic databases ScienceDirect, Pubmed, Medline, Scopus, and Global Health Library. Only those research articles, case studies, case-control studies, case-cohort studies, cross-sectional studies, and organizational survey reports were included in the study that reported any fetal outcomes for pregnant women who had infected with ZIKV during the gestational period and ZIKV-related neurological complications in adults as well. **Results:** Out of total 72 retrieved articles, 50 met the inclusion criteria. We estimated a significant increase in incidence of neural abnormalities such as Guillain–Barre syndrome and microcephaly in the regions that are experiencing ZIKV outbreaks. Other neurological malformations found in ZIKV patients include hydrancephaly/hydrops fetalis, myasthenia gravis, meningoencephalitis and myelitis. **Conclusion:** Our systematic analysis provides the broad spectrum of neurological malformations in ZIKV infected patients and these data further support the causal link of ZIKV with neurological disorders.

1. Introduction

Zika virus (ZIKV) is enveloped, positive sense ssRNA virus that belongs to family Flaviviridae. Since last one year it has spread to almost 84 countries and territories with an increased incidence of central nervous system (CNS) malformations in 33 countries. The first case of ZIKV in human was reported in 1954 in Nigeria[1]. Only 14 cases were confirmed from all across the globe until 2007. However, in 2007, large outbreak was reported in Micronesia, Yap Island where about 5 000 people were infected. Other outbreaks occurred in French Polynesia, Cook Island, Easter Island, Solomon Island, and New Caledonia between 2013 and 2015. ZIKV spread to 20 countries with highest prevalence in Brazil during 2015. The

global bioburden has been raised to 3–4 million cases worldwide with 1.5 million cases confirmed in Brazil[2,3]. Several experimental evidences suggest that this virus is behind the growing incidence of congenital malformation, i.e., microcephaly in neonates and other neurological Guillain–Barre syndrome (GBS), meningoencephalitis, hydrancephaly/hydrops fetalis, myasthenia gravis, and myelitis in adults. The link between ZIKV and catastrophic neurological complications has led to global health emergency. In response to this emerging epidemic, researches have been stirred into action to explore ZIKV vaccine, therapeutics, and consequences. Many cohort studies and case control studies involving pregnant women with ZIKV symptoms have been evaluated to determine the correlation between ZIKV and neurological dysfunctions[4].

First author: Braira Wahid, Centre for Applied Molecular Biology, 87–West Canal Bank Road Thokar Niaz Baig, University of the Punjab, Lahore, Pakistan.

E-mail: brairawahid@gmail.com

✉Corresponding author: Amjad Ali, Centre for Applied Molecular Biology, University of the Punjab, Lahore-53700, Pakistan.

Tel: +92-42-5293141

Fax: +92-42-5293149

E-mail: amjad.camb@pu.edu.pk

This is an open access article distributed under the terms of the Creative Commons Attribution-NonCommercial-Share Alike 3.0 License, which allows others to remix, tweak and build upon the work non-commercially, as long as the author is credited and the new creations are licensed under the identical terms.

For reprints contact: reprints@medknow.com

©2018 Asian Pacific Journal of Tropical Medicine Produced by Wolters Kluwer- Medknow

How to cite this article: Braira Wahid, Amjad Ali, Muhammad Waqar, Muhammad Idrees. An updated systematic review of Zika virus-linked complications. Asian Pac J Trop Med 2018; 11(1): 1–8.

In Brazil, a significant increase in newborns with microcephaly during 2015 has strengthened the connection of ZIKV with microcephaly[2]. From January 2007 to June 2016, 1 551 cases of microcephaly were reported in Brazil, 32 in Colombia, 8 in French Polynesia, 6 in Cabo Verde, 5 in Panama, 4 in Martinique, 2 in America, 1 in Slovenia, 1 in Spain, 1 in Puerto Rico, and 1 in Marshall Islands[5,6]. Ministry of Health, Brazil reported about 4 700 suspected cases of microcephaly during mid-2015 to January 2016, and this incidence was 20 times higher than that between 2010 and 2014.

As of 10 March 2017, 23 countries have reported an increased incidence of GBS. According to World Health Organization, on average 242 ZIKV-linked GBS cases are reported annually in Colombia[1]. As of 8 February 2017, the confirmed number of ZIKV cases in Western Hemisphere countries was 202 008 whereas, 2 588 cases of ZIKV-linked microcephaly in this region has also been reported[7].

Likewise, 252 cases of GBS with ZIKV symptoms were documented during January 2016 in state of Venezuela out of which 66 were reported in state of Zulia[8]. About 169 cases of GBS are reported annually in El Salvador; however, 46 cases including two deaths were reported in this region during ZIKV outbreak (from 1 December 2015 to 6 January 2016)[9]. PAN American Health Organization (PAHO) reported 100 cases of GBS associated with ZIKV from 1st week until 17th week of 2016 in Dominican Republic. Dominican Republic Ministry of Public Health documented a significant increase in GBS cases from 14th week of 2016 and onwards[10]. In Pernambuco state, Brazil seven cases of GBS-linked to ZIKV infection were reported on 25 November, 2015. Immediately after start of ZIKV outbreak during April and June 2015, increased incidence of GBS was confirmed in several states of Brazil. About 130 cases were reported in Pernambuco, 55 in Bahia, 24 in Rio Grande do Norte, 14 in Maranhao, and 6 cases in Paraiba[6]. Likewise, other neural abnormalities such as hydrancephaly/hydrops fetalis, myasthenia gravis, meningoencephalitis and myelitis have also been reported in patients who were positive for ZIKV.

This systematic review presents the key evidences of reported neurological complications in ZIKV-infected people and also speculates increasing risk of teratogenic outcomes during recent outbreak of ZIKV. This study demonstrated the breadth of neurological manifestations of ZIKV.

2. Material and methods

Different databases and PROSPERO-International prospective register for systematic reviews were searched thoroughly to determine if there was any systematic review already published on topics related to ZIKV-linked neurological effects in adults and teratogenic outcomes. None was found. Then, literature search was conducted from June 2016 to March 2017 using different electronic databases such as ScienceDirect, Pubmed, Medline, Scopus, and Global Health Library according to Preferred Reporting Items for Systematic Reviews and Meta-Analyses (PRISMA)

guidelines. We searched databases for publications in English language from early 2015 up to March 2017 to identify potentially eligible studies. Our search terms included ZIKV, neurological abnormalities, hydrancephaly/hydrops fetalis, myasthenia gravis, epidemiology, microcephaly, ovular abnormalities, GBS, myelitis, meningoencephalitis, case-studies, case-cohort studies, cross-sectional studies, organizational survey reports and case-control studies. We reviewed all titles, abstracts, and conclusions of publications. We also studied letters, editorials, and review articles and interacted with experts in the field.

Out of total 72 records, 50 met the inclusion criteria based on reported brain anomalies associated with ZIKV. All articles were reviewed to scan for exclusion criteria. All authors independently screened abstracts, article titles and year of publications to select records for full-text read. Then, we assessed full-texts of articles and consulted other reviewers in case of disagreements so that final decision can be made with mutual consensus. After removing duplicates, review articles, organizational survey reports, letters, and editorials only 39 studies were finally selected for review. Eligible publications included original studies related to ZIKV-linked neurological disorders in fetuses and adults. We finally selected 35 studies for systematic analysis and used spreadsheet to record information such as authors, study area, study period, and finding. A flow chart of our research strategy can be seen in Figure 1.

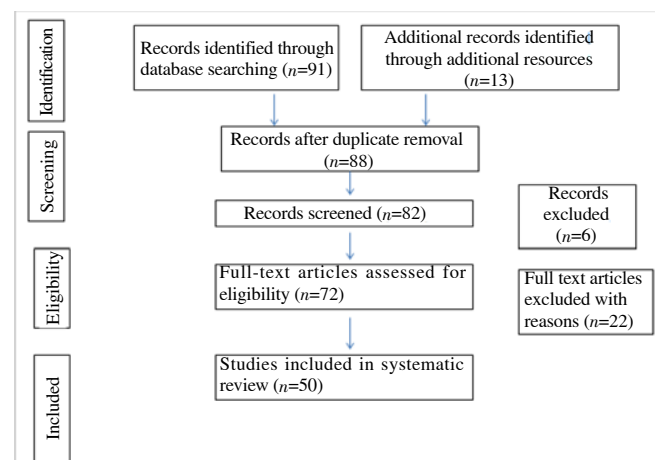


Figure 1. Flowchart defining search strategy.

3. Results

As of March 12, 2017, we retrieved 64 articles that reported neurological fetal outcome in ZIKV-infected pregnant women and other neuro-related disorders in adults. About 35 articles were screened for eligibility and all 35 articles included simple case-studies, case-cohort studies, case-control studies, and cross-sectional studies. The year of publication, location, and frequency of ZIKV-related neuro-disorders in adults as well as neonates were recorded. Out of 35 studies, 15 were related to microcephaly, 16 were related to GBS, 2 studies showed the association of ZIKV with meningoencephalitis, and 2 studies reported acute myelitis in ZIKV-positive patients. Two patients with confirmed diagnosis of ZIKV

experienced hydrops fetalis and myasthenia gravis. According to laboratory confirmed cases and clinical profile studies, microcephaly, GBS, acute myelitis, meningoencephalitis, hydrancephaly/ Hydrops fetalis and myasthenia gravis are presented in Tables 1–3 respectively.

Literature survey shows that microcephaly, GBS, hydrops fetalis, myasthenia gravis, myelitis, and meningoencephalitis are the possible adverse outcomes of ZIKV syndrome. An unprecedented increase in cases of aforementioned brain abnormalities specifically microcephaly during the emergence of ZIKV outbreak has been observed worldwide.

Significant increase in microcephalic newborns was recorded in Brazilian states during 2013 and 2016 compared to previous years. The baseline prevalence of microcephaly was found to be two cases (95% CI: 0–8) per 10 000 neonates in French Polynesia[11,12]. From August to October 2015 about 74% cases of microcephaly related to ZIKV were reported in Brazil[13]. Two studies (simple case report and case-cohort study) demonstrated the association of ZIKV with congenital ocular findings concomitant with microcephaly[14,15]. Two other cases of microcephaly were reported in Rio Grande do Norte and mothers of both fetuses were found to be ZIKV-positive[16]. In another case-control study, ocular findings were confirmed in 34.5%

Table 1

Laboratory confirmed cases and clinical studies of microcephaly.

| References | Study area | Period | Findings |
|------------|---|-----------------------------------|--|
| [11,12] | French Polynesia | October, 2013 to April, 2014 | Higher risk of microcephaly was observed in pregnant women infected with ZIKV during first trimester. Eight cases of microcephaly were identified and the estimated risk of microcephaly was 0.95% (95 cases per 10 000 women infected in the first trimester). |
| [13] | Brazil | August to October, 2015 | Thirty-five infants with microcephaly were included in the study out of which 25 (74%) were positive for ZIKV. |
| [14] | Recife, Brazil | May to December, 2015 | This cross-sectional study included 40 infants with microcephaly of which 22 infants faced ophthalmoscopic alterations as well. |
| [15] | Ljubljana, Slovenia | October, 2015 | A 25-year-old pregnant woman was admitted to University Medical Center in Ljubljana. Neuropathological examination of fetus confirmed microcephaly and RT-PCR assay of fetal brain sample was positive for ZIKV. |
| [16] | Rio Grande do Norte, Brazil | December, 2015 | Formalin-fixed paraffin-embedded tissues samples from two miscarriages and two newborns with microcephaly were collected and submitted to center for disease prevention and control. Laboratory analysis exhibited that all four mothers were positive for ZIKV. |
| [17] | Salvador, Bahia, Brazil | December, 2015 | This cross-sectional study evaluated the ocular findings with microcephaly associated with ZIKV. Ophthalmic examination revealed that 17 out of 29 infants had ocular abnormalities such as chorioretinal atrophy, optic nerve abnormalities, focal pigment mottling of the retina, lens subluxation, and bilateral iris coloboma. |
| [18] | Paraíba, Brazil | 2015 | ZIKV was detected in the amniotic fluid samples of two pregnant women whose fetuses were diagnosed with microcephaly. |
| [19] | Rio de Janeiro | September, 2015 to February, 2016 | This case-cohort study included 88 pregnant women of which 72 were positive for ZIKV and ultrasonography was performed in 42 women. Fetal abnormalities were observed in 12 women. Abnormalities included ventricular calcifications or other central nervous system abnormal amniotic fluid volume or cerebral or umbilical artery flow (7 fetuses) (CNS) lesions (7 fetuses), and in utero growth restriction with or without microcephaly (5 fetuses). |
| [20] | Pernambuco, Brazil | | Relative risk estimates of ZIKV associated microcephaly were evaluated using previously reported estimates. The absolute risk of microcephaly varied between 0% to 30%. The relative risk for Pernambuco state stated that experienced largest outbreak was 100–1 000 (assuming 10% exposure) or 20–200 (assuming 50% exposure) compared to background risk of microcephaly that was around 2 per 10 000 live births in Brazil. |
| [21] | Pernambuco, Paraíba, and Bahia states, Brazil | 2015 | Bahia and Paraíba experienced largest increase in microcephaly cases during epidemiologic weeks 47 and 45 respectively, whereas, in Pernambuco state cases of microcephaly reached a peak during the epidemiologic week 46. |
| [22] | Brazil | 2015–2016 | Until March 2016, number of cases of neurological disorders including microcephaly investigated in Brazil ($n = 4231$) was almost 6 times the number of confirmed cases ($n = 745$). Most of confirmed and notified cases were reported in Rio Grande do Norte, Paraíba, and Pernambuco. The number of confirmed cases associated to ZIKV was small ($n = 88$). A marked increase in the notified cases (58.2%), confirmed cases (223.9%), and ZIKV associated cases ($> 14x$) occurred in 2016. |
| [23] | Brazil | December, 2015, and March, 2016 | Tissue samples from five cases of new born babies with microcephaly and severe arthrogryposis who died after birth were assessed by histopathological examination and RT-PCR analysis. All cases were found to be positive for ZIKV. |
| [24] | Brazil | By June 2016 | All 1 501 liveborn infants were reviewed of whom 602 suspected ZIKV cases were classified into definite cases, highly probable cases, moderately probable cases, somewhat probable cases, and discarded cases. Among 319 definite or probable cases 161 had microcephaly and rash whereas remaining cases had one of two symptoms. |
| [25] | French Polynesia | October, 2013 to March, 2014 | Nineteen cases with brain-stem dysfunction without visible malformations, major brain lesions and severe microcephaly, cerebral lesions without microcephaly. Four of seven tested fetuses with major neurological injuries were infected with ZIKV <i>in utero</i> . |
| [26] | Texas | January 1, 2016 to July 31, 2017 | 80 of the 185 infants, ZIKV-linked microcephaly was observed in 10 neonates and 5 had additional birth defects such as hydranencephaly, holoprosencephaly, clubfeet, and craniosynostosis and other 3 had cataracts, holoprosencephaly, and ventral pons hypoplasia. |
| [27] | Brazil | 2017 | In a mono chorionic diamniotic twin pregnant woman, both fetuses were infected with ZIKV-linked neural deformation because of destruction in neural cells. |
| [28] | Bagota and Cali, Colombia | 2012–2016 | Four fold increases in occurrence of microcephaly has been observed. |

Table 2

Confirmed cases and clinical profile studies of Guillain–Barre syndrome (GBS).

| References | Study area | Period | Findings |
|------------|---------------------------------------|------------------------------------|--|
| [29] | French Polynesia | November 2013 | A woman in her early 40s was brought to French Polynesia Hospital, Tahiti. Diffuse demyelinating disorder GBS was confirmed in electromyogram. Serological analysis indicated presence of ZIKV in the blood. |
| [30,31] | French Polynesia | October, 2013 to April, 2014 | In this case control, 42 patients were diagnosed with GBS. This represented 20-fold rise in incidence of GBS. The study also revealed that about 88% of the patients with GBS were positive for ZIKV. |
| [32] | Martinique, French West Indies Island | January 2016 | Two cases of GBS were reported. ZIKV was detected in the urine of both patients. This island has been experiencing life-threatening ZIKV epidemic since December 2015 with > 1 000 cases per week in 2016. |
| [33,34] | Netherland | 2016 | A 60-year-old woman experienced fever and diarrhea after returning from Surinam a region hit by ZIKV outbreak. ZIKV was detected in her urine and serum and she developed GBS after few weeks of infection. |
| [35] | Haiti | 2016 | A 35-year-old patient was brought to hospital with fever, sensation of electrical currents and bifacial weakness. Patient was diagnosed with facial diplegia variant of GBS. Plaque reduction neutralization test and ELISA showed that he was positive for ZIKV IgM antibodies. |
| [36] | Rio de Janeiro | 2014 | A 24-year-old patient who was found positive for ZIKV and met level III of diagnostic certainty for GBS in the Brighton classification. |
| [37] | Spain | 2016 | A 28-year-old pregnant female with ZIKV positive serology had febrile illness preceding tetraparesis and bulbar nerves compromise was diagnosed with Acute Inflammatory Demyelinating Polyradiculoneuropathy, a variant of GBS. |
| [38] | Brazil | 2005 | The electromyography of 51 year old female patient whose serum was ZIKV positive showed pattern of demyelinating polyneuropathy, characteristic of GBS. |
| [39] | Salvador | 2015 | Female patients of 49 and 22 year age noticed fatigue, lower right limb and upper limb paresis, facial nerve palsy, and dysarthria. Electromyogram pattern showed distal demyelinating disorder with accentuated prolonged distal latencies and minimal reduction of CMAP amplitudes, suggesting an acute inflammatory demyelinating polyneuropathy GBS subtype. |
| [40] | Guyana | 2016 | GBS was confirmed in a 44-year-old male after travelling to South Atlantic Coast in Guyana. |
| [41] | Ecuador | 2016 | Confirmed diagnosis of GBS was made in 57-year-old female patient co-infected with ZIKV and chikungunya virus. |
| [42] | Cucuta, Colombia | December 1, 2015 to April 30, 2016 | Electrophysiological examination, lumbar puncture, and reverse transcriptase-polymerase chain reaction for ZIKV in 14, 10, and 1 patients, respectively led to confirmed diagnosis of GBS in 19 patients. |
| [43] | Colombia | November, 2015 to March, 2016 | About 43% of GBS patients were found to be positive for ZIKV. |
| [44] | Suriname | 2016 | Significant rise in GBS cases have been observed since the start of the ZIKV outbreak in Suriname in October 2015. This study confirmed ZIKV-linked GBS in one of three patients who was in his 60s and his neurological examination revealed absent deep tendon reflexes in the lower extremities but no muscle weakness. |

Table 3

Laboratory confirmed cases and clinical studies of acute myelitis, meningoencephalitis, hydrancephaly/hydrops fetalis, and myasthenia gravis.

| References | Symptoms | Study area | Period | Findings |
|------------|-------------------------------|----------------------------|---------------|--|
| [45] | Acute myelitis | Pointe-à-Pitre, Guadeloupe | January, 2016 | A 15-year-old girl was admitted to hospital with ovarian cyst. Later on, she developed weakness in her left arm, paraesthesia on the left side of her body, and acute lower back pain. Left side hemiplegia got worse and loss of sensation in the legs was also recorded. High concentration of ZIKV was observed on specific real-time reverse PCR 9 d after the onset of symptoms. The observation of ZIKV in cerebrospinal fluid of patient with acute myelitis supports the hypothesis that ZIKV might be neurotropic in nature. This case study indicates that ZIKV have adverse effects on non-pregnant females also. |
| [46] | Acute myelitis | Ribeirão Preto | | A 36-year-old man was presented with fever, malaise, seizures, and headache. The patient died of acute neurological impairment and a pseudotumoral form of ZIKV meningoencephalitis was confirmed by autopsy. |
| [47] | Meningoencephalitis | New Zealand | | A 81-year-old man with comatose, febrile (39.1 °C), Babinski sign on the left side, hemiplegia, and paresis was admitted to ICU. Medical Resonance imaging scan of brain indicated meningoencephalitis. RT-PCR assay of cerebrospinal fluid was positive for ZIKV. This study has proved the association of ZIKV with meningoencephalitis. |
| [48] | Meningoencephalitis | Brazil | 2016 | A 47-year-old Brazilian woman with massive brain swelling, rash, arthralgia, lymphocytic pleocytosis, and dysarthria was brought to hospital. Her RT-PCR analysis for ZIKV was positive in the urine. This was the first fatal case of encephalitis during Brazilian Zika epidemic of 2016. |
| [49] | Hydrancephaly/hydrops fetalis | Salvador, Brazil | 2015 | A 20-year-old ZIKV-infected pregnant woman delivered a dead female fetus 32 nd gestational week. Severe microcephaly, hydrancephaly, intracranial calcifications and destructive lesions of posterior fossa, in addition to hydrothorax, ascites and |
| [50] | Myasthenia gravis | New Caledonia | 2014 | A 45-year-old man with confirmed diagnosis of ZIKV presented with fluctuating weakness of the limbs with areflexia and ptosis of the left eye. Significant decrement of the trapezius muscle to repetitive nerve stimulation was found likewise, another 62-year-old ZIKV-positive man experienced voluntary muscles and diplopia. Both patients showed grade I thymoma. This case report elucidated that myasthenia gravis may mimic Guillain-Barre syndrome, clinicians should be aware of the putative risk of myasthenia gravis following ZIKV infection. |

of ZIKV-linked microcephalic infants[17]. Likewise, mothers of two other microcephalic infants were tested positive for ZIKV[18]. Another case-cohort study reported 28% brain anomalies including microcephaly in newborns whose mothers had infected with ZIKV[19]. Risk of ZIKV-associated microcephaly has increased to 30% (usually varies between 0% to 5%)[20]. In 2015, alarming rise in cases of microcephaly during epidemiologic weeks 45–47 had been observed in three different states of Brazil[20]. Marked increase (> 14 times of previous findings) in confirmed cases of microcephaly was observed in 2016[22]. One study has shown dramatic rise in microcephaly in Paraiba, Bahia, and Pernambuco[51]. Three other prospective studies reported CNS malformations such as brain or cerebral lesions and microcephaly in ZIKV-positive dead and live fetuses[21,23-25].

About 42 cases of GBS were reported in French Polynesia during ZIKV outbreak 2013–2014[52], of which 26 were reported within short period of 8 weeks and this number actually exceeded the GBS baseline incidence that is 3–8 cases a year[53]. During early 2016, two more GBS cases have also been confirmed in Martinique, French West Indies Island[32]. During the current ZIKV outbreak 2016, ZIKV has been confirmed in the urine and serum samples of GBS patients found in Netherlands, Colombia, Haiti, Rio de Janeiro, Spain and Martinique.

Araujo and Ferreira had provided additional evidences of GBS in their review article[54]. A neurologist Mario Emilio Dourado reported seven ZIKV-linked GBS cases in the State of Rio Grande do Norte, Natal City, Northeast Brazil. Four other cases of GBS and two cases of acute disseminated encephalomyelitis associated with ZIKV infection were documented in State of Pernambuco, Northeast Brazil during July 2015. Researchers demonstrated that Brazil experienced 5 times increase in ZIKV-linked GBS since 2015[54]. According to center for disease prevention and control, seven cases of GBS linked to ZIKV infection were reported on 25 November, 2015 in Pernambuco state, Brazil. Immediately after start of ZIKV outbreak during April and June 2015, increased incidence of GBS was confirmed in several states of Brazil. About 130 cases were reported in Pernambuco, 55 in Bahia, 24 in Rio Grande do Norte, 14 in Maranhao, and 6 cases in Paraiba[6]. One case of GBS has also been confirmed in patient co-infected with ZIKV and chikungunya virus[41]. Another male patient in 40s suffered from GBS after travelling to ZIKV endemic region Guyana[40]. A case-control study exhibited 42 cases of GBS in ZIKV-infected patients and showed 20-fold increase in incidence of GBS[31,55]. Nine other cases-reports have also confirmed ZIKV-linked GBS in different regions of world during 2014 to 2017[33-39,42-44,56].

Evidence of ZIKV-linked acute myelitis[45] and meningoencephalitis[47] has been published in The Lancet and New England Journal of Medicine respectively. Evidences of hydrops fetalis and myasthenia gravis have been confirmed in Brazil and New Caledonia, respectively[49,50].

The evidence of ZIKV causing these adverse outcomes in adults

and pregnant women has been the hot topic of debate since ZIKV outbreak in Brazil. Although accumulating evidence have now clarified the lingering questions regarding the confirmed link of ZIKV with potential teratogenic outcomes, the wide spectrum of congenital brain defects discussed in our systematic review also supports the causal relationship of ZIKV with brain anomalies because of increased incidence of neurological malformations reported during recent 2015–2016 outbreak of ZIKV.

4. Discussion

We systematically reviewed many studies reporting the fetal teratogenic effects of ZIKV. Apart from laboratory confirmed cases, animal model studies have also supported the possible association of neurological diseases with ZIKV. It is notable that in this current systematic review, GBS is the most common neurological malformation followed by microcephaly, acute myelitis and meningencephalitis, hydrops fetalis and myasthenia gravis.

According to Tang *et al.*, ZIKV infects human cortical neural progenitor cells (hCNPCs) and the infected cells lead to production of infectious ZIKV particles which cause cell death of hCNPCs. ZIKV infection impedes cell-cycle progression, increases cell death and attenuates growth of hCNPCs[57]. Likewise, ZIKV induced inflammasome activation in the glial cell line U87-MG[58]. Another study reported birth defects caused by Brazilian ZIKV strain in experimental models. In mice, this strain was found to cause microcephaly and intrauterine growth restriction in fetuses. Results of the study exhibit that Brazilian ZIKV cross the placenta, target cortical progenitor cells, induce cell death and impair neurodevelopment[59].

Nowakowski *et al.* elucidated the underlying cellular and molecular mechanisms that associated ZIKV infection to neurological defects[60]. Single-cell RNA expression profiles for cell populations in the human fetal brain were generated and then candidate receptors for ZIKV were surveyed from that dataset. High level of mRNA expression of candidate viral entry receptor AXL was observed in human radial glial cells, endothelial cells, astrocytes, and microglia in developing human cortex; therefore, AXL has been proved as a candidate ZIKV entry receptor in neural stem cells[60]. Likewise, Dang *et al.* developed human embryonic stem cell derived organoid to recapitulate first trimester fetal brain growth. ZIKV was found to infect neural progenitor cells in neurosphere models. ZIKV activated Toll like receptor-3 in cerebral organoids and led to attenuation of neurogenesis[61]. In addition to this, ZIKV activate the death of infected neural cells because of interaction of its capsid protein with mouse double-minute-2 homolog that plays an important role in P53-mediated apoptosis pathway[62]. One study has also shown oncolytic activity of ZIKV against glioblastoma stem cells[63]. ZIKV encoded NS2A degrades adherens junction proteins resulting in disruption of mammalian cortical neurogenesis[64,65].

Garcez *et al.* showed the effects of ZIKV in human neural stem cells growing as brain organoids and neurospheres. Immunocytochemistry and electron chemistry showed that ZIKV reduced the viability and growth of human brain cells[66]. Another ZIKV strain SZ01 targets different neuronal lineages and replicates in the embryonic mouse brain. ZIKV impair cell-cycle, cause apoptosis, and inhibit differentiation of neural precursor cells, leading to microcephaly and cortical thinning. This study provided direct link between ZIKV and brain anomalies, because gene expression analysis of infected brain reveals upregulation of candidate flavivirus entry receptors and dysregulation of genes associated with apoptosis, immune response, and microcephaly[67]. Another study involving two mouse models exhibited affinity of ZIKV to murine neuronal cells thereby supporting the link between ZIKV infection and microcephaly[68]. A recent study retrospectively evaluates the fetal abnormalities due to ZIKV outbreak and found a significant rise in neurological complications in neonates[69]. The main neuroimaging findings observed in different studies include cortical development (e.g., lissencephaly, heterotopia, etc.), brainstem and cerebral, hypoplasia, agenesis of the cavum septum pellucidum, parenchymal calcifications, dysgenesis of the corpus callosum, unilateral or bilateral ventriculomegaly, agenesis of the cavum septum pellucidum, and enlarged extra-axial cerebrospinal fluid spaces[70]. A recent study presented neurological disorders in 12 of 16 patients co-infected with ZIKV, chikungunya virus, and dengue virus in Guayaquil, Ecuador. One patients experienced CNS vasculitis, three had GBS whereas, and six patients were diagnosed with meningitis or encephalitis[71]. Our study reinforces the growing body of evidences associating upsurge in congenital brain malformations with ZIKV by pointing to the worrisome increase in the clinical severity and bioburden of life-threatening brain anomalies[72].

Geographical expansion of ZIKV and unusual rise in magnitude of cerebral malformations also provide basis of ZIKV link with neurological disorders. The causative link of ZIKV with congenital microcephaly and neurological complications worsened the explosive nature of recent epidemics of ZIKV. GBS and microcephaly are the most common brain anomalies whereas, hydrancephaly/hydrops fetalis, myasthenia gravis, meningoencephalitis and myelitis have also been observed in ZIKV infected patients. The findings of our study provide the spectrum of ZIKV-associated brain anomalies. Moreover, this study will act as baseline data for further research. Given the substantial public health implications and rapid geographic spread of ZIKV in recent years, a coordinated global effort and a lot of research work are needed to effectively curb the expansion of current outbreak.

Conflict of interest statement

The authors declare that they have no conflict of interest.

References

- [1] World Health Organization. Zika virus, microcephaly and Guillain-Barré syndrome. [Online]. Available from: <http://www.who.int/emergencies/zika-virus/situation-report/10-march-2017/en/>. Accessed on March 10, 2017.
- [2] Korzeniewski K, Juszczak D, Zwolińska E. Zika—another threat on the epidemiological map of the world. *Int Marit Health* 2016; **67**(1): 31-37.
- [3] Blázquez AB, Saiz JC. Neurological manifestations of Zika virus infection. *World J Virol* 2016; **5**(4): 135.
- [4] Carod-Artal FJ. Epidemiology and neurological complications of infection by the Zika virus: A new emerging neurotropic virus. *Rev Neurol* 2016; **62**(7): 317-328.
- [5] World Health Organization. Zika virus, microcephaly and Guillain-Barré syndrome. [Online]. Available from: <http://www.who.int/emergencies/zika-virus/situation-report/9-june-2016/en/>. Accessed on June 9, 2016.
- [6] European Centre for Disease Prevention and Control. Epidemiological update: Complications potentially linked to the Zika virus outbreak, Brazil and French Polynesia. [Online]. Available from: <https://ecdc.europa.eu/en/news-events/epidemiological-update-outbreaks-zika-virus-and-complications-potentially-linked-24>. Accessed on: 11, 2015.
- [7] Department of Defense, Armed Forces Health Surveillance Branch Global Zika Virus Surveillance Summary. [Online]. Available from: <https://www.google.com/url?sa=t&rct=j&q=&esrc=s&source=web&cd=6&cad=rja&uact=8&ved=0ahUKEwjCyt64o7XAhVEuhoKHUMYBQQFghFMAU&url=http%3A%2F%2Fwww.med.navy.mil%2Fsites%2Fnmcphe%2FDocuments%2Fprogram-and-policy-support%2FAFHSB-Detecting-and-Reporting-DoD-Cases-of-Zika-17%2520MAY-2016.pdf&usg=AOvVaw2J7xMDPFIa9KUj8BqcpqW>. Accessed on January 25, 2017.
- [8] World Health Organization. Guillain-Barré syndrome – Colombia and Venezuela. [Online]. Available from: <http://www.who.int/csr/don/12-february-2016-gbs-colombia-venezuela/en/>. Accessed on 12 February, 2016.
- [9] World Health Organization, Guillain-Barré syndrome – El Salvador. [Online]. Available from: <http://www.who.int/csr/don/21-january-2016-gbs-el-salvador/en/>. Accessed on: 21 January 2016.
- [10] PAN American Health Organization. Zika - Epidemiological Update. [Online]. Available from: http://www.paho.org/hq/index.php?option=com_docman&task=doc_view&Itemid=270&gid=40222&lang=en. Accessed on May 26, 2016.
- [11] Johansson MA, Mier-y-Teran-Romero L, Reefhuis J, Gilboa SM, Hills SL. Zika and the risk of microcephaly. *N Engl J Med* 2016; **375**(1): 1-4.
- [12] Cauchemez S, Besnard M, Bompard P, Dub T, Guillemette-Artur P, Eyrolle-Guignot, et al. Association between Zika virus and microcephaly in French Polynesia, 2013–15: A retrospective study. *Lancet* 2016; **387**(10033): 2125-2132.
- [13] Schuler-Faccini L. Possible association between Zika virus infection and microcephaly—Brazil, 2015. *MMWR Morb Mortal Wkly Rep* 2016; **65**(3): 59-62.
- [14] Ventura CV, Maia M, Bravo-Filho V, Góis AL, Belfort R. Zika virus in

- Brazil and macular atrophy in a child with microcephaly. *Lancet* 2016; **387**(10015): 228.
- [15]Mlakar J, Korva M, Tul N, Popović M, Poljšak-Prijatelj M, Mraz J, et al. Zika virus associated with microcephaly. *N Engl J Med* 2016; **10**(374): 951-958.
- [16]Martines RB. Notes from the field: Evidence of Zika virus infection in brain and placental tissues from two congenitally infected newborns and two fetal losses—Brazil, 2015. *MMWR Morb Mortal Wkly Rep* 2016; **65**(6): 159-160.
- [17]de Paula Freitas B, de Oliveira Dias JR, Prazeres J, Sacramento GA, Ko AI, Maia M, et al. Ocular findings in infants with microcephaly associated with presumed Zika virus congenital infection in Salvador, Brazil. *JAMA Ophthalmol* 2016; **134**(5): 529-535.
- [18]Calvet GA, Filippis AM, Mendonça MC, Sequeira PC, Siqueira AM, Veloso VG, et al. First detection of autochthonous Zika virus transmission in a HIV-infected patient in Rio de Janeiro, Brazil. *J Clin Virol* 2016; **31**(74): 1-3.
- [19]Brasil P, Pereira Jr JP, Moreira ME, RibeiroNogueira RM, Damasceno L, Wakimoto, et al. Zika virus infection in pregnant women in Rio de Janeiro. *N Engl J Med* 2016; **375**: 2321-2334.
- [20]Jaenisch T, Rosenberger K, Brito C, Brady O, Brasil P, Marques E. Estimating the risk for microcephaly after Zika virus infection in Brazil. *Bull World Health Organ* 2017 **95**(3): 191-198.
- [21]de Oliveira WK. Increase in reported prevalence of microcephaly in infants born to women living in areas with confirmed Zika virus transmission during the first trimester of pregnancy—Brazil, 2015. *MMWR Morb Mortal Wkly Rep* 2016; **65**: 242-247
- [22]Cunha AJ, Magalhães-Barbosa MC, Lima-Setta F, Prata-Barbosa A. Evolution of cases of microcephaly and neurological abnormalities suggestive of congenital infection in Brazil: 2015–2016. *Bull World Health Organ* 2016; **94**: DOI: http://www.who.int/bulletin/online_first/zika_open/en/.
- [23]Martines RB, Bhatnagar J, de Oliveira Ramos AM, Davi HP, Iglezias SD, Kanamura CT et al. Pathology of congenital Zika syndrome in Brazil: A case series. *Lancet* 2016; **388**(10047): 898-904.
- [24]França GV, Schuler-Faccini L, Oliveira WK, Henriques CM, Carmo EH, Pedi VD, et al. Congenital Zika virus syndrome in Brazil: A case series of the first 1501 livebirths with complete investigation. *Lancet* 2016; **388**(10047): 891-897.
- [25]Besnard M, Eyrolle-Guignot D, Guillemette-Artur P, Lastère S, Bost-Bezeaud F, Marcelis L, et al. Congenital cerebral malformations and dysfunction in fetuses and newborns following the 2013 to 2014 Zika virus epidemic in French Polynesia. *Euro Surveill* 2016; **21**(13): doi: 10.2807/1560-7917.ES.2016.21.13.30181.
- [26]Hall NB. Notes from the Field: Zika Virus-Associated Neonatal Birth Defects Surveillance—Texas, January 2016–July 2017. *MMWR Morb Mortal Wkly Rep* 2017; **66**(31): 835-836.
- [27]Santos VS, Oliveira SJ, Gurgel RQ, Lima DR, dos Santos CA, Martins-Filho PR. Case Report: Microcephaly in Twins due to the Zika Virus. *Am J Trop Med Hyg* 2017; **97**(1): 151-154.
- [28]Hurtado-Villa P, Puerto AK, Victoria S, Gracia G, Guasmayán L, Arce P, et al. Raised frequency of microcephaly related to Zika virus infection in two birth defects surveillance systems in Bogotá and Cali, Colombia. *Pediatr Infect Dis* 2017; **36**(10): 1017-1019.
- [29]Oehler E, Watrin L, Larre P, Leparac-Goffart I, Lastere S, Valour F, et al. Zika virus infection complicated by Guillain-Barre syndrome—case report, French Polynesia, December 2013. *Eurosurveill* 2014; **19**(9): 20720.
- [30]Cao-Lormeau VM, Blake A, Mons S, Lastère S, Roche C, Vanhomwegen J, et al. Guillain-Barré Syndrome outbreak associated with Zika virus infection in French Polynesia: A case-control study. *Lancet* 2016; **387**(10027): 1531-1539.
- [31]Watrin L, Ghawché F, Larre P, Neau JP, Mathis S, Fournier E. Guillain-Barré syndrome (42 Cases) occurring during a Zika virus outbreak in French Polynesia. *Medicine (Baltimore)* 2016; **95**: 3257-3261.
- [32]Rozé B, Najjoulah F, Fergé JL, Apetse K, Brouste Y, Cesaire R, et al. Zika virus detection in urine from patients with Guillain-Barré syndrome on Martinique, January 2016. *Eurosurveill* 2016; **21**(9): 30154-30156.
- [33]van den Berg B, van den Beukel JC, Alsmas J, van der Eijk AA, Ruts L, van Doorn PA, et al. Guillain-Barre syndrome following infection with the Zika virus. *Ned Tijdschr Geneeskde* 2016; **160**: 155-161.
- [34]Duijster JW, Goorhuis A, van Genderen PJ, Visser LG, Koopmans MP, Reimerink JH, et al. Zika virus infection in 18 travellers returning from Surinam and the Dominican Republic, The Netherlands, November 2015–March 2016. *Infection* 2016; **44**(6): 797-802.
- [35]Kassavetis P, Joseph JM, Francois R, Perloff MD, Berkowitz AL. Zika virus-associated Guillain-Barré syndrome variant in Haiti. *Neurology* 2016; **87**(3): 336-337.
- [36]Brasil P, Sequeira PC, Freitas AD, Zogbi HE, Calvet GA, de Souza RV, et al. Guillain-Barré syndrome associated with Zika virus infection. *Lancet* 2016; **387**(10026): 1482-1486.
- [37]Reyna-Villasmil E, Lopez-Sanchez G, Santos-Bolívar J. Guillain-Barre syndrome due to Zika virus during pregnancy. *Med Clin* 2016; **146**(7): 331-337.
- [38]Fontes CA, dos Santos AA, Marchiori E. Magnetic resonance imaging findings in Guillain-Barré syndrome caused by Zika virus infection. *Neuroradiology* 2016; **58**(8): 837-838.
- [39]do Rosário MS, de Jesus PA, Vasilakis N, Farias DS, Novaes MA, Rodrigues SG, et al. Guillain-Barré Syndrome after Zika virus infection in Brazil. *Am J Trop Med Hyg* 2016; **95**(5): 1157-1160.
- [40]Fabrizius RG, Anderson K, Hendel-Paterson B, Kaiser RM, Maalim S, Walker PF. Guillain-Barré Syndrome associated with Zika virus infection in a traveler returning from Guyana. *Am J Trop Med Hyg* 2016; **95**(5): 1161-1165.
- [41]Zambrano H, Waggoner JJ, Almeida C, Rivera L, Benjamin JQ, Pinsky BA. Zika virus and chikungunya virus coinfections: A series of three cases from a single center in Ecuador. *Am J Trop Med Hyg* 2016; **95**(4): 894-896.
- [42]Arias A, Torres-Tobar L, Hernández G, Paipilla D, Palacios E, Torres Y, et al. Guillain-Barré syndrome in patients with a recent history of

- Zika in Cucuta, Colombia: A descriptive case series of 19 patients from December 2015 to March 2016. *J Crit Care* 2017; **37**: 19-23.
- [43]Parra B, Lizarazo J, Jiménez-Arango JA, Zea-Vera AF, González-Manrique G, Vargas J, et al. Guillain-Barré syndrome associated with Zika virus infection in Colombia. *N Engl J Med* 2016; **375**(16): 1513-1523.
- [44]Langerak T, Yang H, Baptista M, Doornekamp L, Kerkman T, Codrington J, et al. Zika virus infection and Guillain-Barré syndrome in three patients from Suriname. *Front Neurol* 2016; **7**: 233-237.
- [45]Mécharles S, Herrmann C, Poullain P, Tran TH, Deschamps N, Mathon G, et al. Acute myelitis due to Zika virus infection. *Lancet* 2016; **387**(10026): 1481-1486.
- [46]Schwartzmann PV, Ramalho LN, Neder L, Vilar FC, Ayub-Ferreira SM, Romeiro MF, et al. Zika virus meningoencephalitis in an immunocompromised patient. *Mayo Clin Proc* 2017; **92**(3): 460-466.
- [47]Carteaux G, Maquart M, Bedet A, Contou D, Brugières P, Fourati S, et al. Zika virus associated with meningoencephalitis. *N Engl J Med* 2016; **374**(16): 1595-1596.
- [48]Soares CN, Brasil P, Carrera RM, Sequeira P, De Filippis AB, Borges VA, et al. Fatal encephalitis associated with Zika virus infection in an adult. *J Clin Virol* 2016; **83**: 63-65.
- [49]Sarno M, Sacramento GA, Khouri R, do Rosário MS, Costa F, Archanjo G. Zika virus infection and stillbirths: A case of hydropsfetalis, hydranencephaly and fetal demise. *PLOS Negl Trop Dis* 2016; **10**(2): 517-521.
- [50]Molko N, Simon O, Guyon D, Biron A, Dupont-Rouzeyrol M, Gourinat AC. Zika virus infection and myasthenia gravis: Report of 2 cases. *Neurology* 2017; **88**(11): 1097-1098.
- [51]Oliveira CS, Vasconcelos PF. Microcephaly and Zika virus. *J Pediatr* 2016; **92**(2): 103-105.
- [52]Cao-Lormeau VM, Roche C, Teissier A, Robin E, Berry AL, Mallet HP, et al. Zika virus, French polynesia, South pacific, 2013. *Emerg Infect Dis* 2014; **20**(6): 1085-1090.
- [53]Kindhauser MK, Allen T, Frank V, Santhana RS, Dye C. Zika: The origin and spread of a mosquito-borne virus. *Bull World Health Organ* 2016; **94**(9): 675-686.
- [54]Ramos da Silva S, Gao SJ. Zika virus: An update on epidemiology, pathology, molecular biology, and animal model. *J Med Virol* 2016; **88**(8): 1291-1296.
- [55]Cao-Lormeau VM, Roche C, Teissier A, Robin E, Berry AL, Mallet HP, et al. Zika virus, French polynesia, South pacific, 2013. *Emerg Infect Dis* 2014; **20**(6): 1085-1090.
- [56]Oehler E, Fournier E, Leparc-Goffart I, Larre P, Cubizolle S, Sookhareea C, et al. Increase in cases of Guillain-Barré syndrome during a Chikungunya outbreak, French Polynesia, 2014 to 2015. *Euro Surveill* 2015; **20**(48): 30079.
- [57]Tang H, Hammack C, Ogden SC, Wen Z, Qian X, Li Y, et al. Zika virus infects human cortical neural progenitors and attenuates their growth. *Cell stem cell* 2016; **18**(5): 587-590.
- [58]Tricarico PM, Caracciolo I, Crovella S, D'Agaro P. Zika virus induces inflammasome activation in the glial cell line U87-MG. *Biochem Biophys Res Commun* 2017; **492**(4): 597-602.
- [59]Cugola FR, Fernandes IR, Russo FB, Freitas BC, Dias JL, Guimarães KP, et al. The Brazilian Zika virus strain causes birth defects in experimental models. *Nature* 2016; **534**(7606): 267-271.
- [60]Nowakowski TJ, Pollen AA, Di Lullo E, Sandoval-Espinosa C, Bershteyn M, Kriegstein AR. Expression analysis highlights AXL as a candidate Zika virus entry receptor in neural stem cells. *Cell stem cell* 2016; **18**(5): 591-596.
- [61]Dang J, Tiwari SK, Lichinchi G, Qin Y, Patil VS, Eroshkin AM, et al. Zika virus depletes neural progenitors in human cerebral organoids through activation of the innate immune receptor TLR3. *Cell stem cell* 2016; **19**(2): 258-265.
- [62]Teng Y, Liu S, Guo X, Liu S, Jin Y, He T, et al. An integrative analysis reveals a central role of P53 activation via MDM2 in Zika virus infection induced cell death. *Front Cell Infect Microbiol* 2017; **7**: 327-329.
- [63]Zhu Z, Gorman MJ, McKenzie LD, Chai JN, Hubert CG, Prager BC, et al. Zika virus has oncolytic activity against glioblastoma stem cells. *J Exp Med* 2017; **214**(10): 2843-2857.
- [64]Yoon KJ, Song G, Qian X, Pan J, Xu D, Rho HS, et al. Zika-virus-encoded NS2A disrupts mammalian cortical neurogenesis by degrading adherens junction proteins. *Cell Stem Cell* 2017; **21**(3): 349-358.
- [65]Oh Y, Zhang F, Wang Y, Lee EM, Choi IY, Lim H, et al. Zika virus directly infects peripheral neurons and induces cell death. *Nat Neurosci* 2017; **20**(9):1209-1212.
- [66]Garcez PP, Loiola EC, da Costa RM, Higa LM, Trindade P, Delvecchio R, et al. Zika virus impairs growth in human neurospheres and brain organoids. *Science* 2016; **352**(6287): 816-818.
- [67]Garcez PP, Loiola EC, da Costa RM, Higa LM, Trindade P, Delvecchio R, et al. Zika virus impairs growth in human neurospheres and brain organoids. *Science* 2016; **352**(6287): 816-818.
- [68]Tetro JA. Zika and microcephaly: Causation, correlation, or coincidence. *Microbes Infect* 2016; **18**(3): 167-168.
- [69]Silva AC, Moreira JM, Romanelli RM, Teixeira AL. Zika virus challenges for neuropsychiatry. *Neuropsychiatr Dis Treat* 2016; **12**: 1747-1751.
- [70]Mehrdardi MZ, Keshavarz E, Poretti A, Hazin AN. Neuroimaging findings of Zika virus infection: A review article. *Jpn J Radiol* 2016; **34**(12): 765-770.
- [71]Acevedo N, Waggoner J, Rodriguez M, Rivera L, Landivar J, Pinsky B, et al. Zika virus, Chikungunya virus, and dengue virus in cerebrospinal fluid from adults with neurological manifestations, Guayaquil, Ecuador. *Front Microbiol* 2017; **8**: 42-45.
- [72]Cumberworth SL, Barrie JA, Cunningham ME, de Figueiredo DP, Schultz V, Wilder-Smith AJ, et al. Zika virus tropism and interactions in myelinating neural cell cultures: CNS cells and myelin are preferentially affected. *Acta Neuropathol Commun* 2017; **5**(1): 50-51.